

Gross and Histomorphological Studies of Femoral Head Resurfacing in Dog

¹Sharifi, D., ²Razaei, A., ³Savadkouhi, D., ⁴Sadkhanloo, R. and ⁵Rezaeyan; M.

¹Surgery and Radiology Section, Department of Clinical Sciences, Faculty of Veterinary Medicine
University of Tehran, Tehran, Iran

²Surgery and Radiology Section, Department of Clinical Sciences, Faculty of Veterinary Medicine
Islamic Azad University of Tabriz, Tabriz, Iran

³Department of Orthopaedic, Iran University of Medical Sciences, Sina Hospital, Tehran, Iran

⁴Department of Basic Sciences, Anatomy and Histology Section, Faculty of Veterinary Medicine
University of Uremia, Uremia, Iran

⁵Department of Basic Sciences, Anatomy and Histology section, Faculty of Veterinary Medicine
University of Tehran, Tehran, Iran

Abstract: The foetal skull bone as a biological graft was investigated. This study was conducted on Fifteen adult mixed - breed normal dogs 12 to 24 months with weighing 21.4 ± 3.6 Kg. Dogs were randomly divided into 3 groups of 5 animals each. The foetal skull bone of 45 days old was collected from one pregnant bitch via cesarean method. The right femoral head cartilage was removed completely in all dogs of 3 groups. Group I acted as control one, whereas in II group, resurfacing was done by using foetal skull bone which was fixed by using 0.8 mm cerclage wire in criss-cross fashion, but in III group, it was done similar to II group and the hip joint additionally was fixed by using 2 mm steinmann pin. The clinical observations were made accordingly for 60 days in all groups. The gross changes of femoral head in group I & II were quite smooth and slippy, but in III group were uneven and rough due to secondary changes and ankylosis, but on microscopic interpretation there was a remarkable compatibility of the graft with femoral head. The reconstruction of articular cartilage was faster in group II and even group III animals than group I animals. There was single row of chondrocyte in scatter area of samples in group I. The complete and uniform hyaline cartilage in group II and fibro - cartilage and mixture of connective tissues in group III animals were observed. The results indicated that the foetal skull bone due to its pluripotent calvarium easily can orient itself into the chondrocytes and cartilaginous tissues in articular surface of the hip joint, if there is suitable environment before complete ossification, so that normal joint motion could expect.

Key words: Histomorphology, femoral head, resurfacing, foetal skull bone

INTRODUCTION

To improve the reparative response in full thickness cartilage defects, grafting of the denuded area has been performed^[1,2]. The grafting area will result in regenerative tissue that is hyaline in nature and will be able to withstand the mechanical stress during weightbearing better than fibrocartilaginous tissue^[3]. The periosteal^[4] osteochondral^[5,6] and even chondrocyte grafting have been suggested to be used but because of degenerative changes, under long duration of mechanical stress, the foetal skull bone as biological graft was studied on denuded femoral head.

MATERIALS AND METHODS

This study was conducted on 15 clinically healthy adult dogs of either sex, weighing 21.4 ± 3.6 Kg with

12 to 26 months of age, which were randomly divided into 3 groups of 5 animals each. The foetal skull bone of 45 days old was collected after radiographic confirmation from one pregnant bitch via cesarean method. The samples of foetal skull bone were preserved in the ringer solution at 4°C refrigerator temperature and were used within 72 hours after harvesting. After dislocation of right femoral head, the articular cartilage on the femoral head was totally removed using dental bit. The first group acted as control one whereas resurfacing of femoral head was done using foetal skull bone on second group. The graft was fixed using 0.8 mm cerclage wire in criss-cross fashion (Fig. 1). In third group it was done similar to second one but additionally hip joint was fixed using 2 mm in diameter steinmann pin (Fig. 2.) On day 60, macroscopic changes were noted then sample from femoral head in group I, from grafted area in group II

Corresponding Author: Dr: Davood Sharifi, M.V.Sc. & Ph.D., Associate Professor Surgery and Radiology Department of Clinical Sciences Faculty of Vety. Med. University of Tehran, P.O.Box 14155-6453, Tehran - Iran.
Fax: 0098-21-66933222, Tel: 0098-21-66438328, 66920035

and III were collected. Decalcification of samples was done in formic acid and were stained with pantein and stain.

RESULTS

The macroscopic changes of femoral head in group I and II were quite smooth and slippy but in group III due to secondary changes and adhesion between the graft and inner acetabulum surface had uneven and rough surface. There was remarkable compatibility between grafted foetal skull bone and femoral head in group II and III. There were single row chondrocyte and at some part cluster of cells on the articular surface in group I animals. (Fig. 3, 4). Where as complete and uniform hyaline cartilage in group II animal, (Fig. 5). Fibrocartilage and mixture of connective tissue were seen in group III (Fig. 6). There were an indication for foetal skull bone reorientation into cartilagenous tissues on articular surface of femoral head.

DISCUSSION

Selection of the foetal skull bone was for its pluripotent calvarium and having concave surface to obtain a press fit in the circular recipient bed. Postoperative weightbearing lameness was observed in all animals of I and II groups during first week after experiment and nonweightbearing lameness restricted joint mobility in all the animals of group III till end of 60 days. Normal joint stability and the high functional scores of animals in group I and II were attributed to the reduced intra-articular trauma associated with open-joint-surgery and curettage of cartilage too. Anatomical configuration of the femoral head with graft and osseous incorporation of graft in the recipient bed were indication for joint stability and compatibility of the graft with femoral head in group II animals.

The gross muscular atrophy of the operated limb (disuse atrophy) with the lower functional score following joint fixation and secondary local changes were observed in animals group III. The repair seen in animals group I (control) was quite less than which was observed in grafted groups. coordination there was a single of chondrocyte and in some part cluster of cells was observed in group I animals (mals group I (control) was quite less than which was observed in grafted groups. There was a single row of chondrocytes and in some part cluster of cells was observed in group I animals^[7] Fibrocartilage of cartilage defected area with increasing full thickness of cartilage have been reported in horses^[8-10]. There was a similar report^[7] at knee joint of rabbit. There was complete and uniform hyaline cartilage in group II animals which was indicative for foetal skull bone reparative cartilagenous cells to remodel itself into hyaline cartilage with active matrix layer^[11,12] Klilson^[13] reported that following increase in

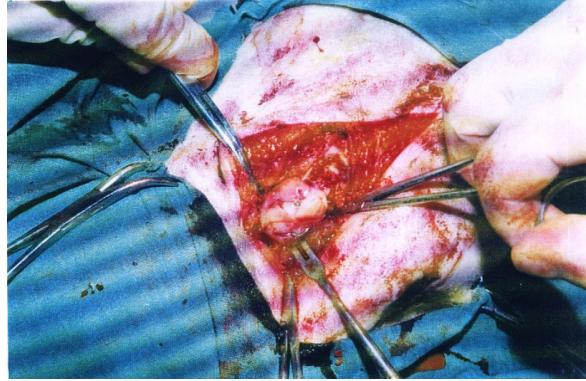


Fig. 1: Fixation of foetal skull bone on femoral head

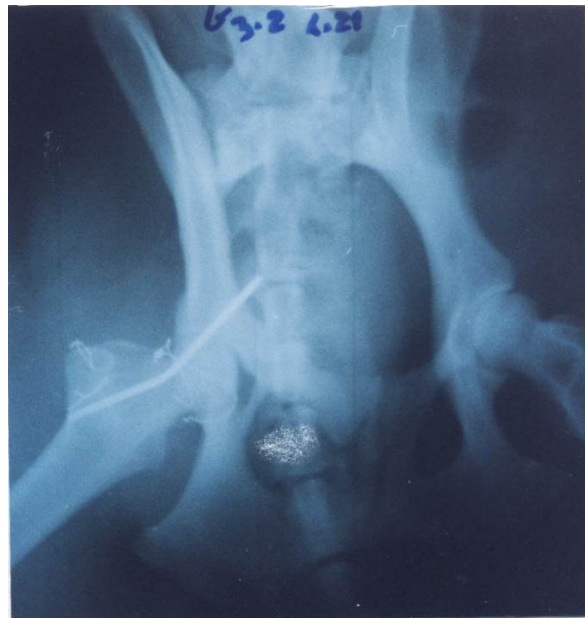

Fig. 2: Immobilization of hip joint in group II

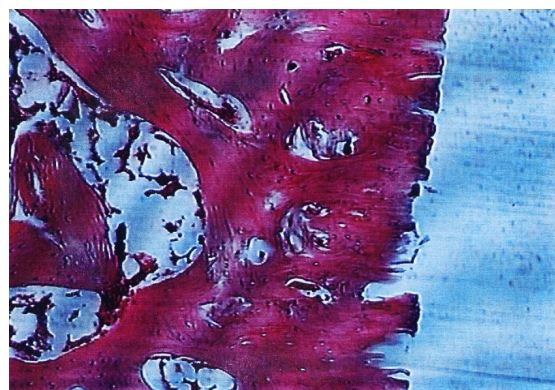


Fig. 3: Section of subchondral bone after complete removed of articular cartilage

joint space there will be usually better maneuvering provided for shaping joint cartilage.

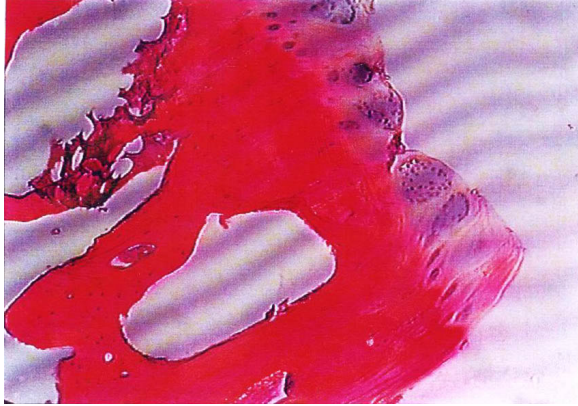


Fig. 4: Single row of chondrocyte with cluster of cells on the articular surface in group I

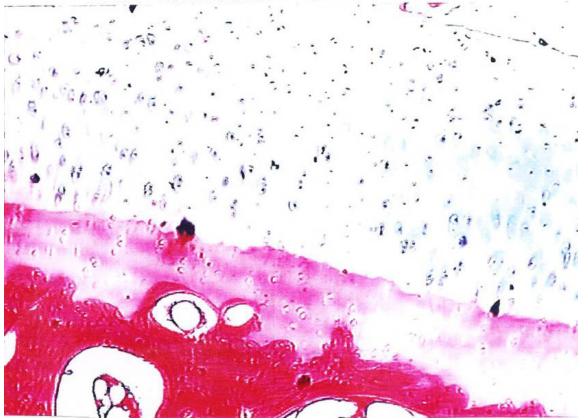


Fig. 5: Hyaline cartilage on articular surface on 60 day in group II

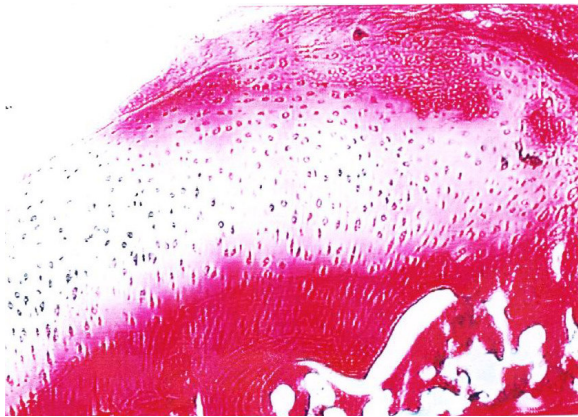


Fig. 6: Fibrocartilagenous deposition on articular surface on 60 day in group III

This study indicated that there was full thickness cartilage like tissues which was originated from foetal skull bone having mesenchymal tissues which further modify itself into cartilage in suitable environment.

The cultured chondrocytes, homologous, foetal and even epiphyseal graft was used in chicken for cartilage defect. Where the site have been completely filled - up with hyaline cartilage^[14].using of chondrocyte cover cartilagenous defected area in 24 weeks, so often this period it has filled up with full thickness of hyaline cartilage containing chondrocytes with high potency of collagen formation^[15]. The defect of adult cartilage doesn't replace by hyaline cartilage in natural reaction^[16,17]. The use of full thickness cartilagenous graft or osteochondral tissue are highly recommended^[1,7].

The mixture of fibrocartilage and connective tissue incorporated with osteochondral bone of femoral head were noticed in animals of group III. Such finding has been reported in rabbits^[18] after fixation of joint for 3 to 6 weeks by using periosteal graft which had hinder effect on cartilage formation leading to local reaction and adhesion which reduced range of joint space and motion^[18,19]. It has been stated that the joint remobilization usually lead to hyaline cartilage differentiation in long term period.^[18] Radiographic finding were supported the result of histological assessment of osseous incorporation of graft with subchondral bone with secondary femoral head changes^[5,20-22]. The results showed that the foetal skull bone before complete ossification placed in suitable environment easily can reorient itself into chondrocytes and cartilagenous tissues in weightbearing articular surface. Percise matching of the size of the donor and hostbone is important for obtaining congruity of the articular surface which is essential to prevent mechanical failure and subsequent degeneration of the joint.

ACKNOWLEDGEMENTS

The authors wish to thank the Faculty of Veterinary Medicine and Tehran University Research Council for approval and financial support for this intensive investigation.

REFERENCES

1. Aston, J.E. and C.C. Bentley, 1986. Repair of articular surfaces by allografts of articular and growth-plate cartilage. *J. Bone. Joint. Surg.* 68(B), 29-23.
2. Musculo, D.L., M.A. Ayerza and M.E. Calabrese, 1996. Human leukocyte antigen mathing, radiographic score and histologic finding in massive frozen bone allografts. *Chin Ortho*, 326: 115-126.
3. Czitrom, A.A., 1994. Biology of Bone Grafting and Principles Of Bone Banking. In Weinstein SL (ed): *The Pediatric Spine: Principles and Practice*. New York, Rawen Press, pp: 1285-1298.

4. Stevenson, S., J.W. Shaffar and V.M. Goldberg, 1996. The humoral response to vascular and nonvascular allografts of bone. *Clin Orthop.*, 323: 86-95.
5. Itay, S., A. Abramovici and A. Nevo, 1987. Use of cultured embryonal chick epiphyseal chondrocytes as grafts for defects in chick articular cartilage. *Clin. Orthop. Rel. Res.*, pp: 220-284.
6. Sulleiss, K.E., C.W. McIlwraith, B.E. Powers and R.W. Norrding, 1985. Evaluation of periosteal graft in articular cartilage repair in horses. *Vet. Surg.*, 14: 66.
7. Cheung, H.S., W.H. Cottell, K. Stephenson and M.E. Nimni, 1978. *In vitro* collagen biosynthesis in healing and normal rabbit articular cartilage. *J. Bone. Joint. Surg.* 60A: 1076.
8. Jaffee, H.L., 1972. Structure of joints, bursal mucosae, tendon sheaths. In *Metabolic Degenerative and Inflammatory Diseases of Bones and Joints*. Philadelphia, Lea & Febiger, pp: 80-104.
9. Paccola, C.A.J., A.M.X. Camilo and R.P. Concalves, 1979. Fresh miniature articular cartilage allografts *Arch. Orthop. Trauma. Surg.*, 43: 253.
10. Stover, S.S., R.R. Pool and A.T. Fischer, 1987. Healing in osteochondral defects: a comparison of articulating and nonarticulating locations. In *Abstracts 33rd Ann. Meet. Orthopaedic Res. Soc.*, Jan 19-22, pp: 275.
11. Depalma, A.F., C.D. McKeever and D.K. Subin, 1966. Process of repair of articular cartilage demonstrated by histology and autoradiography with tritiated thymidine. *Clin. Orthop.*, 48: 229.
12. Etienne, G., M. Mont and H. Khanuja, 2001. Nonvascularized bone graft for osteonecrosis of the femoral head. *Current concepts and techniques. Techniques in Orthopedics*, 16: 39-43.
13. Frost, G.E., 1979. Cartilage healing and regeneration. *J South. Af. Vet. Assoc.*, S: 181-184.
14. Johnson, L.L., 1986. Arthroscopic abrasion arthroplasty histoplasty historical and pathologic perspective: Present status. *Arthroscopy*, 2: 54-59.
15. Rubak, J.M. and V. Pousse, 1982. Effects of joint motion on the repair of articular with free periosteal grafts. *Acta Orthop. Scand.*, 53: 187-191.
16. Bennett, G.A. and W. Bauer, 1935. Further studies concerning the repair of articular cartilage in dog joints. *J. Bone. Joint. Surg.*, 17: 14-150.
17. Lane, J.M., C.T. Brightin and H.R. Ottens, 1977. Joint resurfacing in the rabbit using an autologous osteochondral graft. *J. Bone. Joint. Surg.*, 59A: 218-222.
18. Riddle, W.E., 1970. Healing of articular cartilage in the horse. *J. Am. Vet. Med. Assoc.*, pp: 157-1471.
19. Thompson, R.C.Jr., E.A. Pickuance and D. Garry, 1993. Fractures in large segment allografts. *J. Bone. Joint. Surg. Am.*, 75: 1663-1673.
20. Ivankovick, D.A, A.G. Rosenberg and A. Malamis, 2001. Reconstructive options for avascular necrosis of the femoral head. *Techniques in Orthopedics*, 16: 66-79.
21. Meachim, G. and C. Roberts, 1971. Repair of the joint surface from subarticular tissue in the rabbit knee. *J. Anat.*, 109: 317-327.
22. Rudd, R.G., J.G. Whitehair and J.H. Margolis, 1990. Results of management of osteochondritis dissecans of the humeral head in dog. 44 cases. *J. Am. Anim. Hosp. Assoc.*, 26: 173-178.