

# EFFICACY OF HONEY BEE AND *FAGOPYRUM ESCULENTUM* MOENCH OINTMENT IN THE TREATMENT OF SUB CHRONIC WOUND IN RABBITS: A CASE CONTROL STUDY

Djerrou Zouhir

Institute of Veterinary Sciences, Laboratory of Pharmacology and Toxicology, Constantine 1 University, Algeria

Received 2013-10-26; Revised 2013-11-05; Accepted 2014-01-02

## ABSTRACT

The present study was undertaken to evaluate the efficacy of an ointment of honey bee and *Fagopyrum esculentum* Moench in the management of large dermal wound in a male rabbit wounded accidentally. The wound was covered entirely by honey and then the fine powder of buckwheat grains was added. The treatment was applied once a day until complete epithelization has taken place. The results showed a complete resorption of inflammatory exudate of wound at 4th day. The percentage of wound contraction has shown a rate of 5.55% at the 4th, it has risen to 32.22 and 71.48% at days 7 and 11 respectively to register 99.53% at the 26th days. The epithelization period was 27 days with a mean healing rate of 200 mm<sup>2</sup> day<sup>-1</sup>. The study concludes that the ointment of honey and buckwheat stimulate the healing process in dermal wounds particularly in term of wound contraction. Other studies are underway to understand the possible implication of some amino acids as lysine, proline and glycine presented in buckwheat in the collagen synthesis process.

**Keywords:** Honey, *Fagopyrum Esculentum* Moench, Wound Contraction, Cicatrizing, Rabbit

## 1. INTRODUCTION

Commun buckwheat, *Fagopyrum esculentum* Moench "Syn" *Fagopyrum esculentum* Gilib.), is a gluten-free pseudo cereal belonging to Polygonaceae family. This crop was very popular food during 17th-19th century and was later abandoned during the 20th century in Western countries because of the competition with wheat (Cawoy *et al.*, 2009). It is native to central Asia and grows wild in Manchuria and Siberia. It is cultivated for human consumption and for livestock and poultry feeds. It is a source of buckwheat honey as well (Tahir and Farooq, 1988). According to a review of Shin *et al.* (2010), Buckwheat has been widely considered as a nutritious and medicinal food with various health benefits, i.e., cholesterol reduction (Kayashita *et al.*, 1997), hypertension regulation (Ma *et al.*, 2006), diabetes (Kawa *et al.*, 2003), tumor inhibition (Chan, 2003) and control of inflammation and carcinogenesis (Ishii *et al.*, 2008).

Honey is a natural complex produced by honeybees, *Apis mellifera*, known since ancient times for its

nutritional and medicinal purposes. Honey has been used in many cultures for its medicinal properties, including the management of burns, cataracts, ulcers and wound healing (Coulston, 2000). Honey has been shown to possess antimicrobial, antiviral, antiparasitary, antiinflammatory, antioxidant, antimutagenic and antitumor effects (Bogdanov *et al.*, 2008).

The present study was undertaken to evaluate the efficacy of an ointment of honey and buckwheat seeds powder in the management of a large dermal wound, in a rabbit wounded accidentally.

## 2. MATERIALS AND METHODS

### 2.1. Description of Case

A New Zealand male rabbit of 8 months old with a sub chronic large caudal wound **Fig. 1**. The wound has not been cicatrized since 03 months due to the permanent conflict with other rabbits (5) living in the same cage (surface of 1.2 m<sup>2</sup>). After separation of the rabbit in an individual standard cage, it has been consulted.

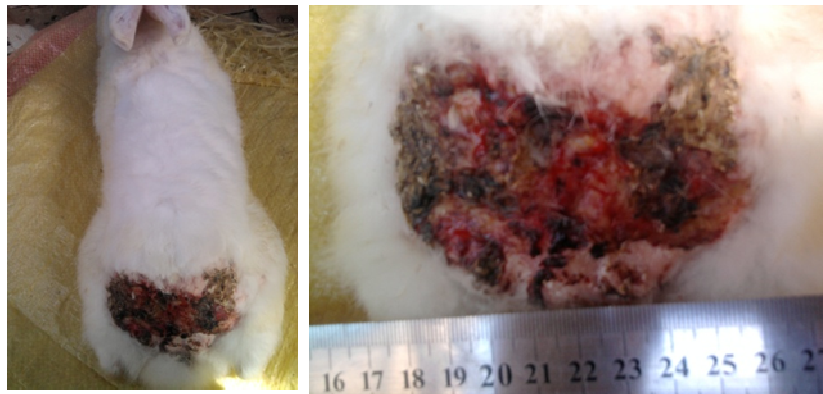

Fig. 1. Rabbit with large caudal wound

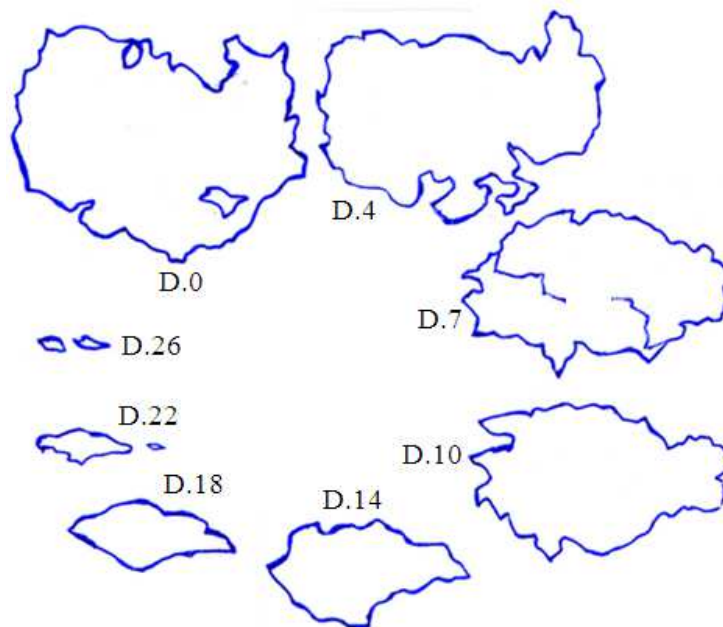


Fig. 2. Chronological evolution of rabbit's wound traced on a transparent sheet

It has presented a rectal temperature of 38.5°C, a 35 respiratory movements/minute and a cardiac frequency of 70 battements/minute.

## 2.2. Drugs and Treatment

*Fagopyrum esculentum* Moench grains were purchased from a local farmer. The fruits were exposed to sun light for 5 h and then were ground in to a fine powder. Honey was purchased from a local flower beekeeper.

The wound was treated once a day until day 25. First the entire surface of wound was covered by honey and then powder of buckwheat was added to form an ointment on the wound.

## 2.3. Evaluation of Healing Process

The limits of wound were traced on a transparent paper in days 0, 4, 7, 11, 14, 18, 22 and 26 **Fig. 2**. The correspondent surfaces were then determined. The percentages of wound contraction were consecutively calculated according to the following equation:

Percentage of wound contraction

$$= \frac{\text{Surface D0} - \text{Surface Dx}}{\text{Surface D0}} \times 100$$

Surface D0 (before treatment) = 54 cm<sup>2</sup>, Surface Dx: Surface calculated in each day. The epithelization period was determined when the percentage of wound contraction is 100%. The weight of rabbit was determined each 7 days to follow its general state.

### 3. RESULTS

Despite the large surface of animal's wound (54 Cm<sup>2</sup>) (Fig. 1), the rabbit has presented normal rectal temperature, respiratory movements and cardiac frequency. The body weight has not changed

significantly during the first 15 days (1840 g at d0, 1839 g at 7th day and 1845 at 14th day). In the following 2 weeks, the weight has registered a sensitive elevation (2010 g at 21st days and 2065 at 28th days).

The application of honey bee and *Fagopyrum esculentum* Moench grains powder to the wound has stimulated the healing process. At the 4th day the inflammatory exsudate of wound was entirely resorbed and a thick crust was formed Fig. 3. The retraction of wound was remarkably important one week after treatment Fig. 2 and 3. The percentage of wound contraction Fig. 4 has shown a rate of 5.55% at 4 day, it has risen to 32.22 and 71.48% at days 7 and 11 respectively to register 99.53 % at d 26. The epithelization period was 27 days with a mean healing rate of 200 mm<sup>2</sup> day<sup>-1</sup>.

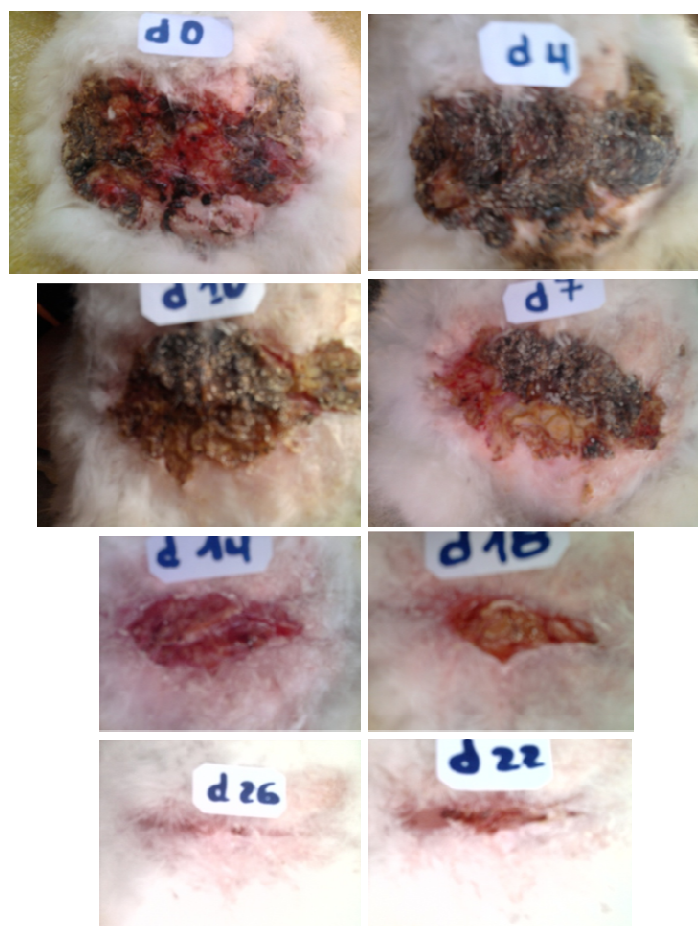
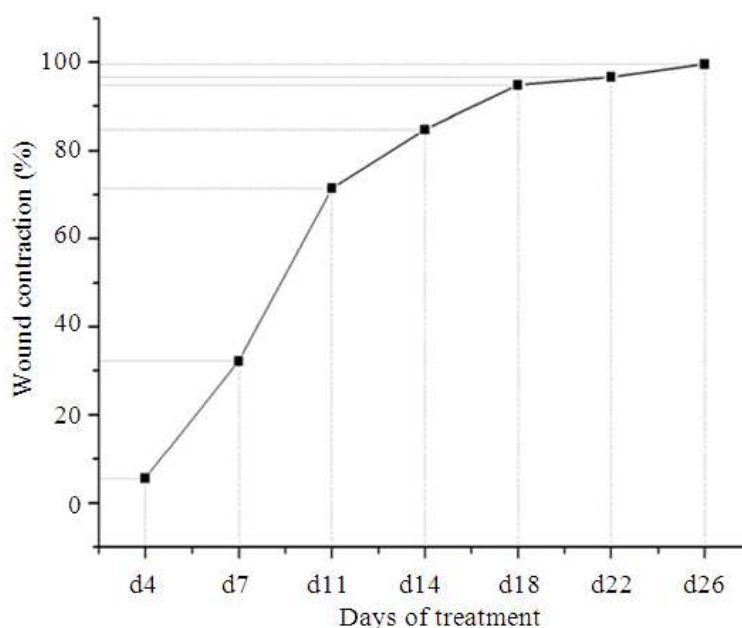


Fig. 3. Photographic presentation of the chronological evolution of rabbit's wound



**Fig. 4.** Percentage of wound contraction

#### 4. DISCUSSION

Wound healing is stepwise process, which consists of different phases such as hemostasis, inflammation, proliferative and remodeling (Kaushik *et al.*, 2013). This process is often negatively affected by microbial infection or pathological condition leading into a development of chronic wound (Polakovicova *et al.*, 2011). Some standard drugs have failed in the management of this kind of wounds. Facing this problem, scientists have attributed a great importance to natural products looking for new most active molecules with less toxicity.

Several studies have focused the pharmacological properties of honey, among them cicatrizing activity. Honey provides a protective barrier and owing to its high osmolarity, creates a moist wound-healing environment and prevents bacterial colonization. Thus, honey reduces inflammation and also reduces exudates formation more promptly than standard treatments (Coulston, 2000). We mention here that a study of Khalil *et al.* (2012) conducted on honey samples from Algeria; they have concluded that honey from this country has a high antioxidant potential. They have found strong positive correlations between flavonoïd, proline and ascorbic acid contents and color intensity with DPPH and FRAP values.

Concerning buckwheat, for our knowledge, there are no scientific published reports describing the implication of this pseudo cereal in the management of wounds. However the ointment of honey and buckwheat fruits powder was used in traditional medicine, by some families in eastern Algeria, in the treatment of large burns.

Buckwheat grains contain carbohydrates (71%) represented mainly by starch, proteins (9.77%), lipids (1.73%) minerals and vitamins (1.72), fibers (3.7), water (12.8%), fatty acids, amino acids (glycine:0.79, lysine:0.58, proline: 0.48%...) (Souci, 2008). It is known that these later amino acids are necessary to collagen synthesis. The triple-helix formation is initiated after synthesis of the procollagen polypeptide chains. It is resulting in a repeating XaaYaaGly sequence, where Xaa and Yaa can be any amino acid. The amino acids in the Xaa and Yaa positions of collagen are often (2S)-proline (Pro, 28%) and (2S,4R)-4-hydroxyproline (Hyp, 38%), respectively. ProHypGly is the most common triplet (10.5%) in collagen (Shoulders and Raines, 2009). In view of these scientific reports, it appears that the combination of honey and buckwheat offers a good nutritional and antioxidant potential. It could provides a moist environment and exert an antimicrobial and anti-inflammatory effects on wound. This ointment provides

also considerable amounts of nutriment particularly some essential amino acids like lysine, proline and glycine and vitamin C which are implicated in the formation of collagen synthesis precursors (procollagen and tropocollagen).

## 5. CONCLUSION

The present case has shown remarkable effects of an ointment of honey bee and *Fagopyrum esculentum* Moench grains powder in the stimulation of dermal wound healing. The beneficial effects of this ointment were noted in the inflammatory phase, the stimulation of wound contraction and the amelioration of healing time. More controlled studies are needed to confirm the healing properties of buckwheat alone and in case of interaction with honey bee. The isolation of these pseudo cereal components and assessment of their cicatrizing potential are also recommended to understand the mechanism of action behind this pharmacological property and to identify the specific chemotypes implicated.

## 6. REFERENCES

- Bogdanov, S., T. Jurendic, R. Sieber and P. Gallmann, 2008. Honey for nutrition and health: A review. *Am. J. Coll. Nutr.*, 27: 677-689. PMID: 19155427
- Cawoy, V., J.F. Ledent, J.M. Kinet and A.L. Jaquemart, 2009. Floral biology of common buckwheat (*Fagopyrum esculentum* Moench). *Eur. J. Plant Sci. Biotechnol.*, 3: 1-9.
- Chan, P.K., 2003. Inhibition of tumor growth in vitro by the extract of *Fagopyrum cymosum* (fago-c). *Life Sci.*, 72: 1851-1858. PMID: 12586222
- Coulston, A.M., 2000. Honey how sweet it is. *Nutr. Today*, 35: 96-100.
- Ishii, S., T. Katsumura, C. Shiozuka, K. Ooyauchi and K. Kawasaki *et al.*, 2008. Anti-inflammatory effect of buckwheat sprouts in lipopolysaccharide-activated human colon cancer cells and mice. *Biosci. Biotechnol. Biochem.*, 72: 3148-3157. PMID: 19060399
- Kaushik, M., A. Kaushik and K. Murti, 2013. Exploration of healing promoting potentials of leaves of *Morus alba* L. in albino rats. *Am. J. Pharmacol. Toxicol.*, 8: 95-101. DOI: 10.3844/ajptsp.2013.95.101
- Kawa, J.M., C.G. Taylor and R. Przybylski, 2003. Buckwheat concentrate reduces serum glucose in streptozotocin-diabetic rats. *J. Agric. Food Chem.*, 51: 7287-7291. PMID: 14640572
- Kayashita, J., I. Shimaoka, M. Nakajoh, M. Yamazaki and K. Norihisa, 1997. Consumption of buckwheat protein lowers plasma cholesterol and raises fecal neutral sterols in cholesterol-fed rats because of its low digestibility. *J. Nutr.*, 127: 1395-1400. PMID: 9202097
- Khalil, M.I., M. Moniruzzaman, L. Boukraâ, M. Benhanifia and M.A. Islam *et al.*, 2012. Physicochemical and antioxidant properties of Algerian honey. *Molecules*, 17: 11199-11215. DOI: 10.3390/molecules170911199
- Ma, M.S., I.Y. Bae, H.G. Lee and C.B. Yang, 2006. Purification and identification of angiotensin I-converting enzyme inhibitory peptide from buckwheat (*Fagopyrum esculentum* Moench). *Food Chem.*, 96: 36-42. DOI: 10.1016/j.foodchem.2005.01.052
- Polakovicova, S., S. Polak, M. Kuniakova, M. Cambal and J. Majtan *et al.*, 2011. The effect of salivary gland extract of *Lucilia sericata* maggots on the human dermal fibroblasts proliferation. *Online J. Biol. Sci.*, 11: 96-100. DOI: 10.3844/ojbsci.2011.96.100
- Shin, D.H., A.H.M. Kamal, T. Suzuki, Y.H. Yun and M.S. Lee *et al.*, 2010. Reference proteome map of buckwheat (*Fagopyrum esculentum* and *Fagopyrum tataricum*) leaf and stem cultured under light or dark. *Aus. J. Crop Sci.*, 4: 633-641.
- Shoulders, M.D. and R.T. Raines, 2009. Collagen structure and stability. *Annu. Rev. Biochem.*, 78: 929-58. DOI: 10.1146/annurev.biochem.77.032207.120833
- Souci, F.K., 2008. La Composition Des Aliments. Table aux Des Valeurs Nutritives. 7th Edn., MedPharm Scientific Publishers.
- Tahir, I. and S. Farooq, 1988. Review article on buckwheat. *Fagopyrum*, 8: 33-53.